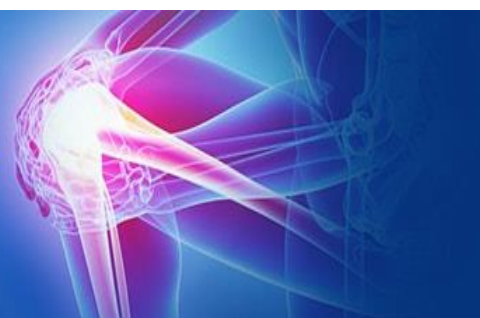



ISSN (P): 2521-3466
ISSN (E): 2521-3474
© Clinical Orthopaedics
www.orthoresearchjournal.com
2021; 5(3): 161-163
Received: 16-05-2021
Accepted: 18-06-2021

Dr. Rajib Debnath
Assistant Professor, Department
of Orthopaedics, Tripura Medical
College & DR BRAM Teaching
Hospital, Hapania, ONGC,
Agartala, West Tripura, India

Dr. Pradyot Basak
Assistant Professor, Department
of Orthopaedics, Tripura Medical
College & DR BRAM Teaching
Hospital, Hapania, ONGC,
Agartala, West Tripura, India

Dr. Abhijit Sarkar
Professor and HOD, Department
of Orthopaedics, Tripura Medical
College & DR BRAM Teaching
Hospital, Hapania, ONGC,
Agartala, West Tripura, India

Dr. Varun Phogat
Senior Resident, Department of
Orthopaedics, Sanjay Gandhi
Memorial Hospital, New Delhi,
Delhi, India

Corresponding Author:
Dr. Pradyot Basak
Assistant Professor, Department
of Orthopaedics, Tripura Medical
College & DR BRAM Teaching
Hospital, Hapania, ONGC,
Agartala, West Tripura, India

Assessment of factors resulting to functional outcome of intertrochanteric fracture of femur managed by proximal femoral nail: Antirootation 2 (PFNA 2)

Dr. Rajib Debnath, Dr. Pradyot Basak, Dr. Abhijit Sarkar and Dr. Varun Phogat

DOI: <https://doi.org/10.33545/orthor.2021.v5.i3c.310>

Abstract

Background: Intertrochanteric femur fracture management in elderly needs more attention to reduce malunion and increase early mobilisation to reduce mortality and morbidity. Ideal choice of treatment is internal fixation by intramedullary or extramedullary devices. Intramedullary devices provide more stable proximal femoral anatomical fixation. Between PFN and PFNA; helical blade in PFAN provides more stability, better compression and rotational control with lower cut-out rate.

Aim: a) To assess the factors for functional outcome of PFNA2. b) Evaluation of effectiveness and stability of PFNA 2.

Material and Methods: 30 patients with unstable Intertrochanteric femur fracture between Nov 2020 to July 2021 fulfilling inclusion and exclusion criteria were included in this study and underwent closed reduction and internal fixation by PFNA(n=30). Assessment was done in terms of demography, preoperative and intraoperative variables, postoperative parameters mainly functional outcome till 1 year postoperative.

Results: Preoperative variables, AO fracture type were assessed preoperatively. Duration of surgery, blood loss and fluoroscopy imaging were significantly lower in PFNA as compared to PFN. Postoperative complications like cut-out rate, shortening, varus malalignment, return to pre-fracture state were also lower in PFNA group than PFN. Postoperative functional assessment done by Harris Hip Score shows better outcome in PFNA than other fixation devices.

Conclusion: PFNA reduces duration of surgery, blood loss, fluoroscopy imaging as compared to other implants. PFNA also offers better postoperative functional outcome.

Keywords: PFNA- proximal femoral nail antirotation, PFN- proximal femoral nail

Introduction

Globally, incidence of proximal femoral fractures are increasing day by day as life expectancy and osteoporosis in elderly has been increased worldwide^[1, 2, 3].

Number of trochanteric femur fractures are predicted to be 1.6 million by 2025 and 2.5 million by 2050. Similarly number expected to be 32% in 2025 and 38% in 2050^[4].

Earlier inadequate trochanteric fracture treatment leads to acute instability and chronic malunion with deformity and functional restriction.

With advance of orthopaedic treatment, surgical fixations are replacing conservative treatment to achieve accurate anatomical and stable reduction with rigid internal fixation to start early mobilisation and to prevent complications.

The strength of fracture fixation mainly depends on a) bone quality b) fracture geometry c) reduction d) implant design & placement.

Intramedullary implants provide lesser surgical exposure, minimal blood loss, may require increased fluoroscopy exposure.

Biomechanically, intramedullary implants allow stable anatomical fixation without abductor arm shortening or changing the proximal femoral anatomy.

In PFNA, helical blade instead of conventionally used two screws, provides better stability, compression as well as rotational control. Hence less chance of cut-out and implant failure rate.

Material and Methods

The study was conducted, Department of Orthopaedics, Tripura Medical College & DR BRAM Teaching Hospital. Hapania, P.O.: O.N.G.C, Agartala, West Tripura, between Nov 2020 to July 2021, a prospective study of 30 patients conducted in a tertiary care centre. In which, 30 cases were operated by PFNA2. Intraoperative data as duration of surgery, blood loss, number of fluoroscopy images taken were documented. Clinical and radiological assessment of fracture union/ complications for all the patients were done pre & post operatively at 6 weeks, 3 months, 6 months. Harris Hip Scoring system was used at 6 month for the functional outcome assessment.

Results

Mean age was 67.33 years. Gender distribution showed 67% female & 33% male. AO fracture type 31A-2.2 were maximum

number of cases (73.33%) as in Table 1.

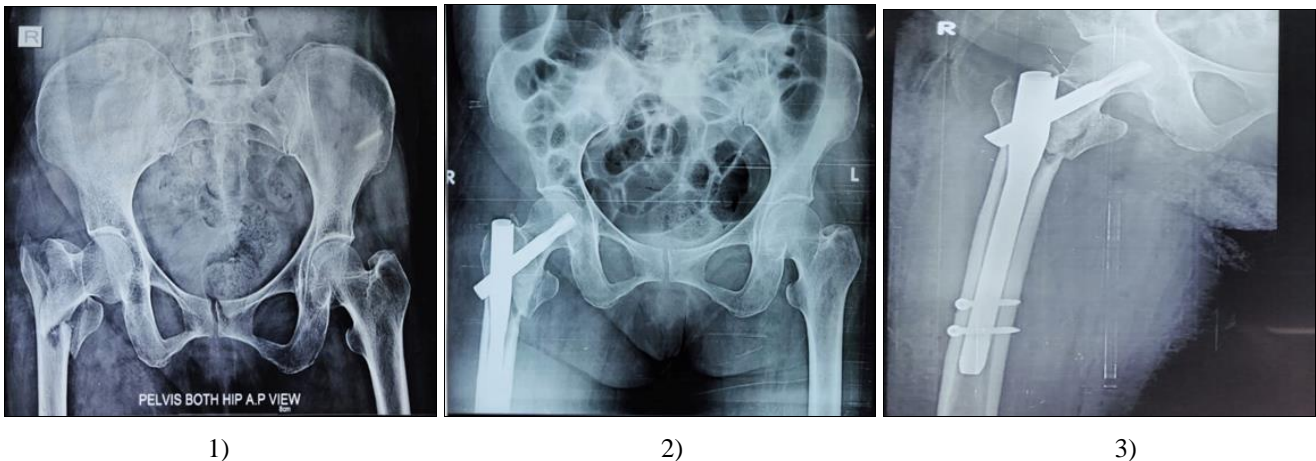
Table 1: Gender distribution

Characteristic	PFNA (N=30)
Mean age(years)	67.33
Range(min to max)	56-79
Females	20(67%)
MALES	10(33%)
31A-2.2	22(73.33%)
31A-2.3	4(13.33%)
31A-3.1	2(6.66%)
31A-3.2	2(6.66%)

The mean operative time was 49 minutes. Blood loss during the surgical procedure was very minimal and significant difference noted than other implants, as in table 2.

Table 2: indicating blood loss while surgical Procedure.

Operative detail	PFNA(N=30)
Mean duration	49
Range	40-70
Blood loss < 100ml	12(40%)
Blood loss > 100ml	18(60%)
Mean image	18
Range	15-25

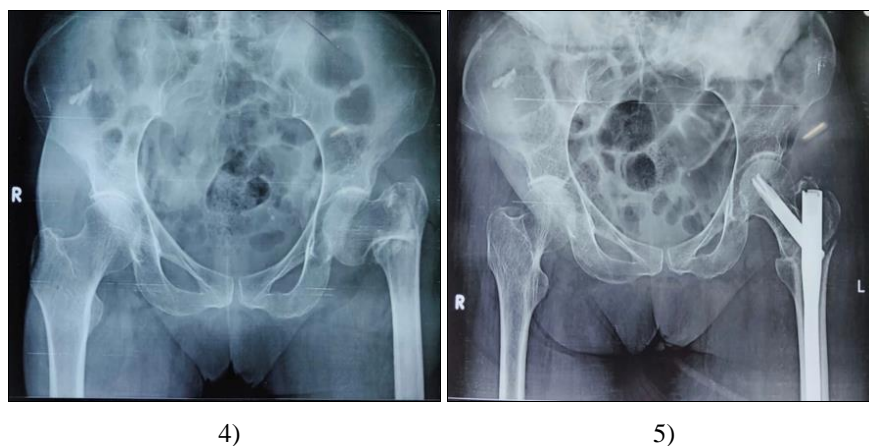


1)

2)

3)

Fig 1, 2, 3: Preoperative and Postoperative x-rays of PFNA2 fixation in 80 years old female



4)

5)

Fig 4, 5: Preoperative and Postoperative x-rays of PFNA2 fixation in 70 years old female

The mean number of images taken intraoperative was significantly lower in PFNA2.

The cutout/ z- effect rate was 6.66% in PFNA2 cases.

Complications such as shortening more than 1 cm were noted in 13.33% PFNA2 cases, varus malalignment were 6.66% in PFNA2 cases as in Table 3.

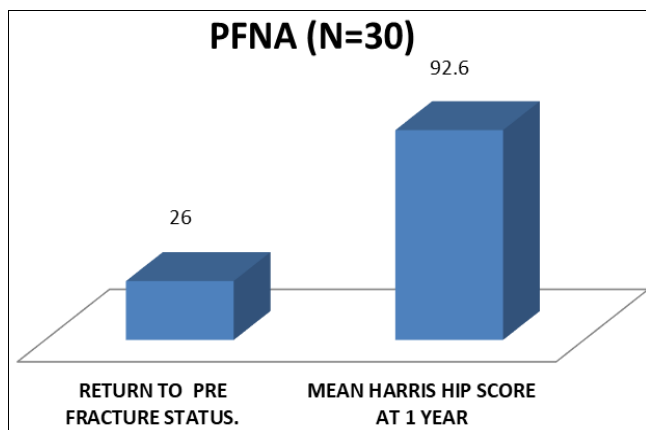
Table 3: Complications.

Postoperative complications	PFNA (N=30)
Cut out / z- effect	2(6%)
Shortening > 1 cm	4(13%)
Varus malalignment	2(6.66%)

26 patients in PFNA were returned to pre fracture status. The mean Hip Harris Score at 6 month postoperative of PFNA2 cases were well accepted and satisfactory as in Table 4, And Figure 6.

Table 4: Final Results.

Final outcome measures	PFNA (N=30)
Return to pre fracture status.	26 (86.66%)
Mean harris hip score at 1 year	92.6

**Fig 6:** Final Results of our study.

Discussion

Intertrochanteric femur fracture in elderly increases morbidity and also increases complications due to prolonged bed rest (bed sore, deep venous thrombosis, pulmonary infections). In elderly patients, osteoporosis is leading because for worsening of quality of fixation thus increases implant failure rates. Aim of intertrochanteric femur fracture management is mainly early fixation and mobilization [5].

Intramedullary implants provide more biological advantages than extramedullary implants [6].

Mean operation time, blood loss and intraoperative fluoroscopy images were lower in PFNA cases than PFN because of the use of helical blade in PFNA over dual screws in PFN. Zeng *et al.* noted that PFNA fixation reduces duration of surgery, complication rate, implant failure and intraoperative blood loss as compared to PFN [7].

Takigami *et al.* concluded that surgical time and operative blood loss were lower with use of PFNA than PFN [8]. Similar results were found in our study.

In our study, total 3 cut-out cases reported where 2 cases in PFN and 1 case in PFNA. 20% cases in PFN and 13% in PFNA showed shortening >1cm similarly lower rate of varus malalignment noted in PFNA patients.

Andrej in his study recommended a TAD (tip apex distance) of 20- 30 mm in case of helical blade as compared to conventional screws and also found that cut out rates were higher if tad was >30 mm or < 20 mm [9].

More *et al.* observed that PFNA is implant of choice for intertrochanteric femur fracture fixation in elderly [10].

The mean harris hip score at 1 year postoperative showed better results in PFNA patients than PFN.

Conclusion

Surgical fixation by PFNA showed significant benefits in terms of duration of surgery, intraoperative blood loss, complications and functional outcome.

The prospective nature of the study strengthened the study whereas smaller sample size and shorter duration of follow-up are limiting factors.

References

- Korkmaz MF. Outcomes of trochanteric femoral fractures treated with proximal femoral nail: an analysis of 100 consecutive cases. *Clinical Interventions in Aging* 2014; 569. doi:10.2147/cia.s59835.
- Kashid MR. Comparative study between proximal femoral nail and proximal femoral nail antirotation in management of unstable trochanteric fractures. *International Journal of Research in Orthopaedics* 2016;2:354.
- Salphale Y. Proximal Femoral Nail in Reverse Trochanteric Femoral Fractures: An Analysis of 53 Cases at One Year Follow-Up. *Surgical Science* 2016;07:300-308.
- Melton LJ. Secular trends in hip fracture incidence and recurrence. *Osteoporosis International* 2009;20:687-694.
- Panula J. Mortality and cause of death in hip fracture patients aged 65 or older-a population-based study. *BMC Musculoskeletal Disorders* 2001, 12.
- Imren Y. Biomechanical comparison of dynamic hip screw, proximal femoral nail, cannulated screw, and monoaxial external fixation in the treatment of basicervical femoral neck fractures. *Acta Chir. Orthop. Traumatol. Cech* 2015;82:140-144.
- Zeng C, Wang YR, Wei J, Gao SG, Zhang FJ, Sun ZQ *et al.* Treatment of trochanteric fractures with proximal femoral nail antirotation or dynamic hip screw systems: a meta-analysis. *J Int Med Res* 2012;40(3):839-51.
- Takigami I, Matsumoto K, Ohara A, Yamanaka K, Naganawa T, Ohashi M *et al.* Treatment of trochanteric fractures with the proximal femoral nail antirotation (PFNA) nail system – report of early result. *Bull NYU Hosp Jt Dis* 2008;66(4):276-9.
- Nikoloski AN, Osbrough AL, Yates PJ. Should the tip-apex distance (TAD) rule be modified for the proximal femoral nail antirotation (PFNA)? A retrospective study. *J Orthop Surg Res* 2013;8:35.
- Mora A, Marimon I, Rius M, Brill W, Corral A, Gaya S. PFN versus PFNA in treatment of trochanteric femoral fractures: A prospective study. *Bone and joint journal Orthopaedic proceedings* 2011;93(2):136.